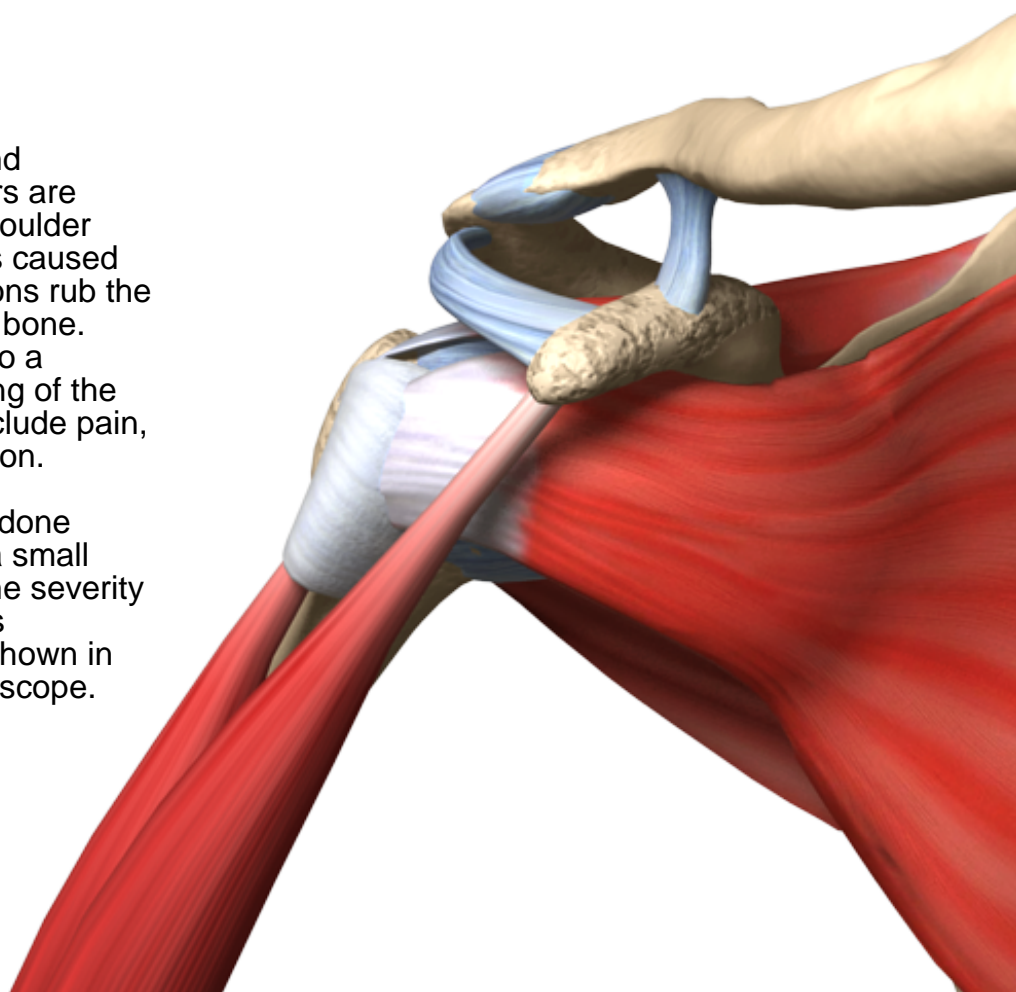
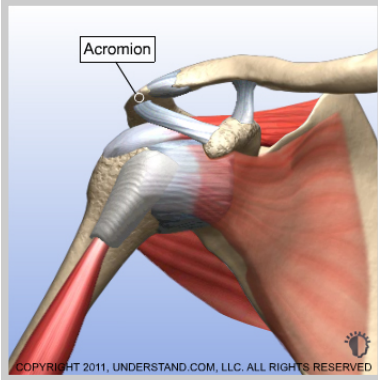


Partially Torn Rotator Cuff

Impingement syndrome and associated rotator cuff tears are commonly encountered shoulder problems. This condition is caused when the rotator cuff tendons rub the underside of the acromion bone. Chronic rubbing can lead to a weakening and even tearing of the rotator cuff. Symptoms include pain, weakness and loss of motion.

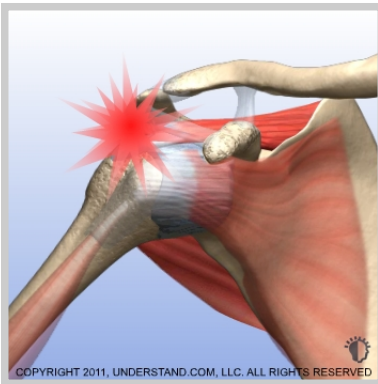Whether this procedure is done using a scope or through a small incision is dependent on the severity of the tear and the doctor's preference. The method shown in these animations is with a scope.





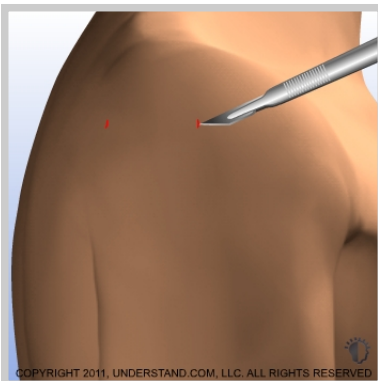
Partially Torn Rotator Cuff Introduction

Impingement syndrome and associated rotator cuff tears are commonly encountered shoulder problems. This condition is caused when the rotator cuff tendons rub the underside of the acromion bone. Chronic rubbing can lead to a weakening and even tearing of the rotator cuff. Symptoms include pain, weakness and loss of motion. Whether this procedure is done using a scope or through a small incision is dependent on the severity of the tear and the doctor's preference. The method shown in these animations is with a scope.



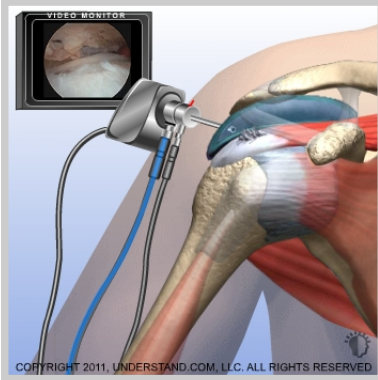
Rotator Cuff Pain

The underside of the acromion bone rubs the rotator cuff tendons causing pain and weakness. More space will be created for the rotator cuff by removing part of the acromion.



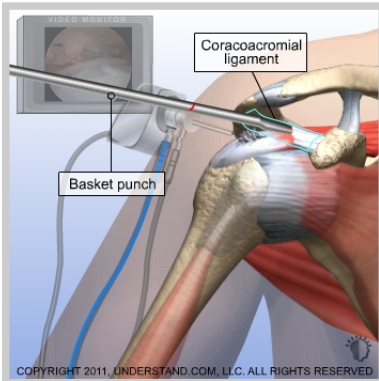
Incisions

Small incisions (portals) are made around the joint. The scope and surgical instruments will go into these incisions.



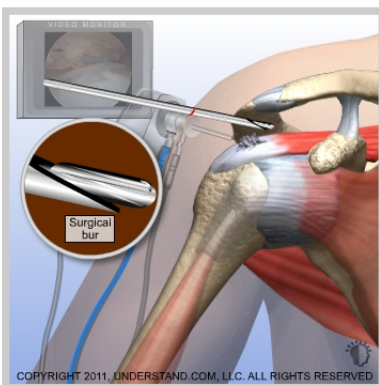
Visualization

The scope is inserted into the back of the shoulder joint. Saline solution flows through a tube (cannula) and into the bursa sac to expand the joint and to improve visualization. The image is sent to a video monitor where the surgeon can see inside the joint.



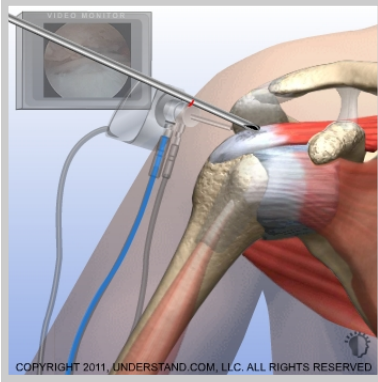
Bursa Sac and Coracoacromial Ligament Removal

A specialized surgical instrument is used to remove the inflamed and irritated bursa sac. Next, a surgical instrument is inserted into the joint and, based on surgeon discretion (or decision), the coracoacromial ligament is removed.



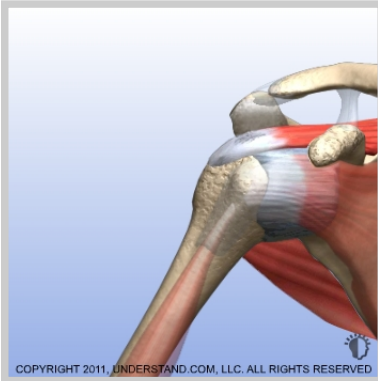
Removing Bone

A surgical burr is used to remove bone from the underside of the acromion. More space is created for the rotator cuff tendons.



Shaving Frayed Rotator Cuff Edges

The shaver blade is used again, this time to remove the frayed edges of the rotator cuff.



End of Procedure

After more space has been created for the rotator cuff and the frayed edges have been trimmed, the procedure is completed.